



PATIENT

Pema Anasoulis

PRESENTING CLINICAL SIGNS

History: Grade III/VI heart murmur. Doing well - good appetite and water intake. BP: 162, 163, 165mmHg. *Sedated with Torb/Alfaxalone/Midazolam.

SPECIES

Feline

ECHOCARDIOGRAM FINDINGS

2D, m-mode, color flow and Doppler imaging is available.

BREED

DSH

Left ventricle: The LV chamber is decreased with adequate myocardial function. The LV wall thicknesses are markedly increased. There is a diffusely hyperechoic endocardium consistent with fibrosis. The papillary muscles are severely hypertrophied and hyperechoic. The endocardium appears mildly remodeled.

SEX

Male Neutered

Left atrium: The left atrium is mildly enlarged. No smoke or thrombi seen.

Mitral valve: The anterior leaflet of the mitral valve is thickened. Systolic anterior motion is seen on 2D imaging. Mild eccentric MR.

AGE

15 years

Aortic valve/Aorta: The aortic valve is normal in morphology and mobility. Moderately increased aortic outflow velocity with a dynamic profile. No aortic insufficiency.

Right ventricle: Normal right ventricular diameter and morphology indicating no overt evidence of pulmonary arterial hypertension.

Right atrium: The right atrium is normal in dimension.

Tricuspid valve: The tricuspid valve appears normal with no tricuspid regurgitation.

WEIGHT

14.1lbs

Pulmonary valve/Pulmonary artery: The pulmonic valve is normal in morphology and mobility. No pulmonic insufficiency. Normal RVOT velocity.

Pericardium/other: No pericardial or pleural effusion noted. No obvious cardiac masses.

Heart rhythm: ECG reveals a sinus rhythm with an average HR of 180bpm.

INTERPRETED BY

Maggie Machen
Lamy, DVM
DACVIM (Cardiology)

2-Dimensional Measurements

Ao diam (cm)	1.0
LA diam (cm)	1.4
LA:Ao (Swe)	1.4
IVS thickness (cm)	0.73
LVID diastole (cm)	1.1
PW thickness (cm)	0.90
LVID systole (cm)	0.4
FS (%)	67

Doppler Measurements

PV Vmax (m/s)	0.6
AoV Vmax (m/s)	3.5
MR Vmax (m/s)	NA
TR Vmax (m/s)	NA
TR PG (mmHg)	NA

IMAGING

PERFORMED BY

Pamela Harrigan,
RDCS

INTERPRETATION OF THE FINDINGS

The diagnosis and cause of the murmur is hypertrophic obstructive cardiomyopathy (HOCM). This indicates some degree of LV thickening (marked in this case) with a dynamic LVOT obstruction (SAM). There is mild left atrial dilation, indicating the risk for progression to spontaneous CHF and/or a thrombotic event is currently low. No additional issues are identified.

HOSPITAL NAME

Norfolk County
Veterinary Service

REFERRING VET

Dr. Richards

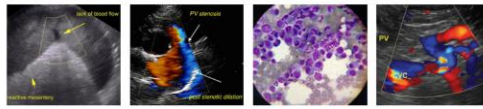
While no medications have been shown to definitively alter long term outcome at this stage of disease, atenolol is often initiated to decrease the outflow obstruction. This is recommended in this case given the degree of hypertrophy and suspected severe LVOT obstruction when not sedated. If there is difficulty medicating at home, an alternative approach would be closely monitoring for progression in the next 6 months; however, given the degree of LVOT hypertrophy I would recommend initiation at this time if possible. Prognosis is guarded given the severity of disease in this senior cat. Patient will

INVOICE

29203

DATE

2/23/23



PATIENT Pema Anasoulis always be risk for progression to CHF, development of blood clots and/or sudden death in the future.

RECOMMENDATIONS

- SPECIES** Feline
- If able, administer titrating dose of atenolol: 25mg tablets; Give ¼ tab once daily. Recheck heart rate in 1-2 weeks with target stressed rate of 140-160bpm 12-24 hours post-administration. Increase as needed until target reached.
 - Screening BP/T4 if not recently performed.
- BREED** DSH
- Anesthetic risk is considered elevated, with high risk for fluid overload, spontaneous CHF, hypotension, etc. Judicious IV fluid rates are advised to avoid fluid overload. Drugs that stimulate heart rate should be avoided unless clinically necessary (glycopyrrolate, atropine). Avoid ketamine, telazol, acepromazine and Dexdomitor.
- SEX** Male Neutered
- Monitor for any clinical evidence of cardiac compromise, including respiratory changes and/or signs of a blood clot event (paralysis, neurologic changes, etc.).

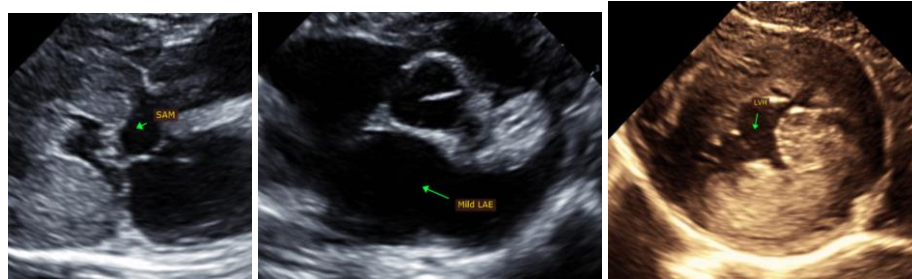PLAN

- AGE** 15 years
- Recommend recheck echocardiogram in 6 months to assess rate of progression, sooner if any issues arise in the interim.

IMAGES

WEIGHT 14.1lbs

INTERPRETED BY
 Maggie Machen Lamy, DVM
 DACVIM (Cardiology)



IMAGING PERFORMED BY Pamela Harrigan, RDCS

The information and recommendations provided are based on the images presented by the referring veterinarian. No evaluation can be communicated regarding pathology that was not visible in the image/video clips provided.

Thank you for this referral. This report was generated using transcription software, and minor dictation errors may be present. If the clinical or image interpretation does not parallel your findings or if I can be of any further assistance, please contact me.

HOSPITAL NAME
 Norfolk County
 Veterinary Service

Maggie Machen Lamy, DVM
 Diplomate of the American College of Veterinary Internal Medicine (Cardiology)
 info@sonopath.com

REFERRING VET
 Dr. Richards

Echocardiogram performed by: Pamela Harrigan, RDCS
 Pet Animal Ultrasound Service (4paus.com)

INVOICE
 29203

DATE
 2/23/23